

**PATIENT**

Emma Anderson

**PRESENTING CLINICAL SIGNS**

History: Exercise -induced collapse of 1 month duration. ThyroTab .8 BID.

**SPECIES**

Canine

**RADIOGRAPHIC FINDINGS** \*NOTE: Images submitted for supplemental cardiac information only.  
Normal cardiac silhouette. No obvious evidence of CHF.

**BREED**

Lab Mix

**ELECTROCARDIOGRAPHIC FINDINGS** \*Note: Single lead ECGs are evaluated as a rhythm strip. Morphology/MEA cannot be definitively commented on.

A single lead ECG is available from an AliveCor monitor; 50mm/s, 20mm/mV. The average heart rate is 110bpm (range 88-136bpm). The rhythm is sinus in origin, with a p for every QRS complex and vice versa. Short PR; possible delta wave. The P and QRS morphologies are positive with normal dimension. No ectopic beats, pauses or other dysrhythmias observed.

**SEX**

Female Spayed

ECG diagnosis: Normal sinus rhythm with respiratory variation. Possible PR abnormality.

**AGE**

6 years

**ECHOCARDIOGRAM FINDINGS**

2D, m-mode, color flow and doppler imaging is available. Mild diffuse thickening of mitral valve leaflets with no obvious prolapse into the left atrial lumen. Trace central mitral regurgitation with mild left atrial dilation. No significant LV dilation; however, the systolic function is moderately depressed. The tricuspid valve appears normal with mild tricuspid regurgitation. Normal right atrial and ventricular diameter and morphology indicating no overt evidence of pulmonary arterial hypertension. The pulmonic and aortic valves are normal in morphology and mobility. Normal pulmonic and aortic outflow velocities with laminar flow. No AI or PI. No pericardial or pleural effusion noted. No obvious cardiac masses.

**WEIGHT**

87lbs

**INTERPRETED BY**

Maggie Machen Lamy,  
DVM, DACVIM  
(Cardiology)

**CARDIAC CHART**

**IMAGING PERFORMED BY**

Rebekah Jakum, CVT  
ARDMS/RVT

CANINE CARDIAC PARAMETERS	MR VMAX (m/s)	TR VMAX (m/s)	LA/AO (Boon method)	LA/AO (Heart Base; Swe)	FS (%)	EF (%)	EPSS (cm)
NORMAL PARAMETER	4.5-5.5	<2.7	1.3	<1.6	28-40	40-100	<0.6
PATIENT	NM	NM	NM	1.5	17	30	0.5
CANINE CARDIAC PARAMETERS	HR (BPM)	AV VMAX (m/s)	PV MAX (m/s)	BODY WEIGHT (kg)	LA 2D short axis Base view (cm)	LVIDd Avg; 2D and m-mode short axis (cm)	LVIDs Avg; 2D and m-mode short axis (cm)
NORMAL PARAMETER	50-100	0.7-1.7	0.7-1.6	BELOW	BELOW	BELOW	BELOW
PATIENT	130	1.3	0.9	39.5	3.0	4.6	3.8
*Normal chamber parameters expressed as a mean value (SD)				3	1.27 (5.3)	2.46 (2.46)	1.36 (5.5)
BODY WEIGHT DEPENDENT PARAMETERS				5	1.40 (4.5)	2.74 (5.2)	1.60 (4.7)
*Note: All measurements based upon multi-modal images and methods. An average value is reported.				10	1.50 (3.8)	3.27 (3.5)	2.06 (3.1)
				15	1.83 (2.0)	3.71 (2.4)	2.43 (2.1)
				20	2.02 (1.9)	4.14 (2.2)	2.80 (2.0)
				25	2.18 (2.4)	4.48 (2.9)	3.10 (2.5)
				30	2.33 (3.3)	4.83 (3.9)	3.39 (3.4)
				35	2.48 (4.3)	5.17 (5.0)	3.69 (4.5)
				40	2.62 (5.2)	5.48 (6.1)	3.96 (5.4)
				50	2.88 (7.1)	6.07 (8.3)	4.46 (7.4)

**HOSPITAL NAME**

Alburtis Animal Hospital

**REFERRING VET**

Dr. Smith

**INVOICE**

24440

**DATE**

5/26/22

Adapted from June Boon, Veterinary Echocardiography, 1998  
Rishniw M and Hollis NE, J Vet Intern Med 2000; 14:429-435  
Hansson et al, Vet Rad and Ultrasound 2002  
Bonagura et al. Echocardiography: principles of interpretation, Vet Clin North Am 15:1177, 1995



**PATIENT**

Emma Anderson

**SPECIES**

Canine

**BREED**

Lab Mix

**SEX**

Female Spayed

**AGE**

6 years

**WEIGHT**

87lbs

**INTERPRETED BY**

Maggie Machen Lamy,  
DVM, DACVIM  
(Cardiology)

**IMAGING PERFORMED BY**

Rebekah Jakum, CVT  
ARDMS/RVT

**HOSPITAL NAME**

Alburtis Animal  
Hospital

**REFERRING VET**

Dr. Smith

**INVOICE**

24440

**DATE**

5/26/22

**INTERPRETATION OF THE FINDINGS & FURTHER RECOMMENDATIONS**

Mild left heart changes are identified, with moderate systolic dysfunction; however, the LV chambers are not significantly dilated. While this may reflect a normal variant; however, this is atypical especially in a young dog and follow up is certainly advised. Mild left atrial enlargement indicates a low risk for complication at this time. No additional issues are identified.

Systolic dysfunction can be primary in nature (DCM) or secondary to taurine deficiency, myocarditis, tachycardia-induced cardiomyopathy, thyroid imbalance, or infiltrative disease such as lymphoma. A hypothyroid dog, a thyroid level should be submitted, if not recently checked. Given the recent evidence of grain free/boutique diets leading to DCM in some (but certainly not all) dogs, **highly recommend a thorough diet history in this patient.** If grain free, boutique brand or exotic ingredient, recommend immediate change to a more standard well formulated diet. Additionally, a taurine level can be submitted, however regardless of results recommend a taurine supplement in this case as below. No clear indication for Pimobendan at this juncture, however if any progression is noted this will be advised. Prognosis is open until progression is determined.

The ECG is largely unremarkable, with no dysrhythmias observed. Of note in this breed is a short PR interval. This may reflect an atypical conduction pathway, may be a normal variant, or may simply be due to device insensitivity. In light of the breed predisposition and collapse episodes, highly recommend referral for a 6 lead tracing.

Even with mild changes identified here this does not clearly explain syncopal episodes. That being said, if they occur with significant exertion there may be a correlation with LV dysfunction. The ECG finding may suggest a propensity for supraventricular tachycardia; however, this is considered unlikely. As mentioned above referral and/or a holter monitor should be considered, particularly if no alternative explanation for the episodes is found through systemic work up. More historical information may be useful such as situational component, length, etc.

Monitor for development of a heart murmur, cough, labored breathing, exercise intolerance or collapse episodes. Omega fatty acid supplementation and mild salt restriction may be of some long-term benefit.

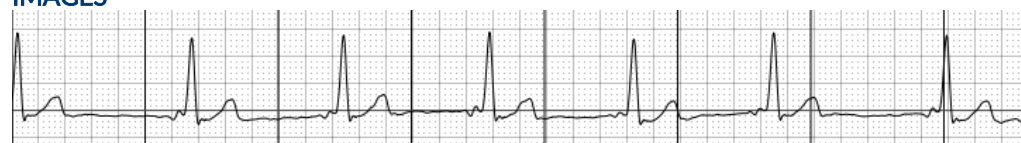
Anesthesia is not recommended until further evaluation is performed.

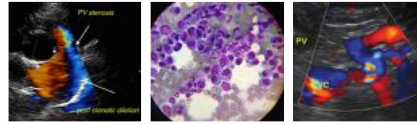
**PLAN**

Diet history and thyroid level recommended as discussed. Recommend Taurine 1000mg PO q12h. Consider a six-lead ECG tracing, holter monitor, full systemic evaluation, etc. as discussed.

Recommend conservative monitoring with a recheck echocardiogram in 6 months, sooner if any worsening of clinical signs.

**IMAGES**





**PATIENT**

Emma Anderson

**SPECIES**

Canine

**BREED**

Lab Mix

**SEX**

Female Spayed

**AGE**

6 years

**WEIGHT**

87lbs

**INTERPRETED BY**

Maggie Machen Lamy,  
DVM, DACVIM  
(Cardiology)

**IMAGING  
PERFORMED BY**

Rebekah Jakum, CVT  
ARDMS/RVT

**HOSPITAL NAME**

Alburtis Animal  
Hospital

**REFERRING VET**

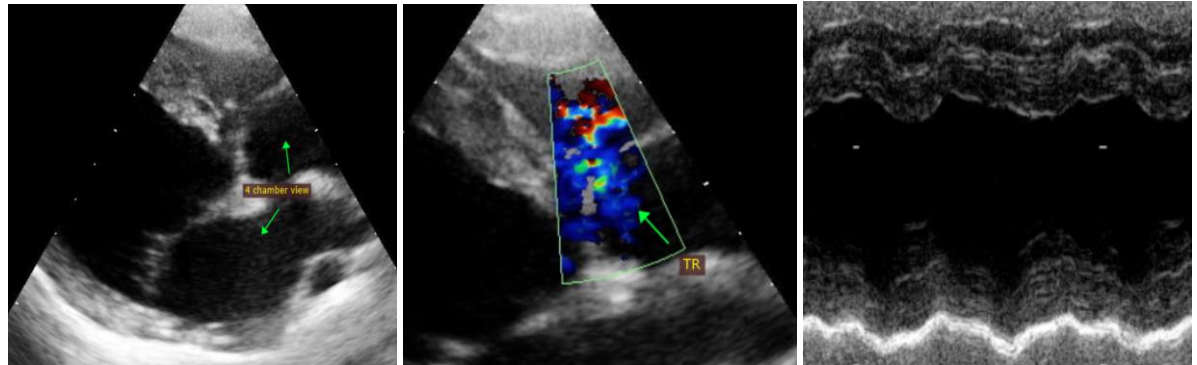
Dr. Smith

**INVOICE**

24440

**DATE**

5/26/22



The information and recommendations provided are based on the images presented by the referring veterinarian. No evaluation can be communicated regarding pathology that was not visible in the image/video clips provided.

Thank you for this referral. This report was generated using transcription software, and minor dictation errors may be present. If the clinical or image interpretation does not parallel your findings or if I can be of any further assistance, please contact me.

Maggie Machen Lamy, DVM  
Diplomate of the American College of Veterinary Internal Medicine (Cardiology)  
info@sonopath.com